

Hypercalcemia Associated With Severe Dysphagia in a Patient with Parathyroid Adenoma and Significant Cervical Spondylophytes

Čulina, Duje; Peček, Mirta; Gregurić, Tomislav; Aras, Ivana; Košec, Andro; Stevanović, Siniša

Source / Izvornik: **Clinical Case Reports, 2024, In Press**

Journal article, Published version

Rad u časopisu, Objavljena verzija rada (izdavačev PDF)

<https://doi.org/10.1016/j.aace.2024.02.004>

Permanent link / Trajna poveznica: <https://um.nsk.hr/um:nbn:hr:257:605042>

Rights / Prava: [Attribution-NonCommercial-NoDerivatives 4.0 International/Imenovanje-Nekomercijalno-Bez prerada 4.0 međunarodna](#)


Download date / Datum preuzimanja: **2025-01-22**



Repository / Repozitorij:

[SUVAG Polyclinic Repository](#)





Case Report

Hypercalcemia Associated With Severe Dysphagia in a Patient With Parathyroid Adenoma and Significant Cervical Spondylophytes

Duje Čulina, MD ^{1,*}, Mirta Peček, MD ², Tomislav Gregurić, MD, PhD ³,
Ivana Aras, MD, PhD ⁴, Andro Košec, MD, PhD, FEBORL-HNS ^{1,5},
Siniša Stevanović, MD, PhD ¹

¹ Department of Otorhinolaryngology and Head and Neck Surgery, University Clinical Centre Sestre Milosrdnice, Zagreb, Croatia

² Institute of Emergency Medicine of Virovitica County, Virovitica, Croatia

³ Department of Radiology, University Clinical Centre Sestre Milosrdnice, Zagreb, Croatia

⁴ SUVAG Zagreb, Croatia

⁵ School of Medicine, University of Zagreb, Zagreb, Croatia

ARTICLE INFO

Article history:

Received 5 December 2023

Received in revised form

15 February 2024

Accepted 20 February 2024

Available online xxx

Key words:

severe dysphagia

hypercalcemia

parathyroid adenoma

parathyroid gland

ABSTRACT

Background/Objective: Severe dysphagia is a rare presenting symptom of primary hyperparathyroidism, whereas the most common hypercalcemia-related causes include gastrointestinal symptoms, such as anorexia, constipation, and pancreatitis. This case presentation aimed to describe swallowing difficulty as a leading symptom of hypercalcemia.

Case Report: A 62-year-old man experienced vomiting, dysphagia bordering with aphagia, and 20-kg weight loss in a 2-month period. The parathyroid hormone and serum calcium levels were 102 pmol/L (reference range, 1.8-7.9 pmol/L) and 4.12 mmol/L (reference range, 2.14-2.53 mmol/L), respectively. Ultrasound-guided exploration of the neck revealed a large, rounded hypoechoic mass inferior to the left thyroid lobe, which contained parathyroid tissue on fine-needle aspiration cytology examination. Contrast-enhanced neck computed tomography revealed a mass measuring 3.6 × 2.6 × 2.5 cm behind the left thyroid lobe, alongside massive ventral spondylophytes of the cervical spine at the level of the postcricoid segment of the hypopharynx. Magnetic resonance imaging confirmed ventral tissue displacement due to spondylophyte size and location. Surgical exploration of the left side of the neck was performed, and the left lower parathyroid gland weighing 9.07 g was excised. Pathohistologic findings verified a parathyroid gland adenoma. The postoperative values showed parathyroid hormone and serum calcium levels at 4.54 pmol/L and 2.25 mmol/L, respectively.

Discussion: The pathophysiology of dysphagia in hypercalcemia is not fully elucidated. In this case, the patient's improvement after surgery implies a plausible connection between hypercalcemia and dysphagia, suggesting a causal relationship.

Conclusion: Although aphagia is not a typical presenting symptom of parathyroid adenoma, it should be noted in the differential diagnosis.

© 2024 AAACE. Published by Elsevier Inc. This is an open access article under the CC BY-NC-ND license (<http://creativecommons.org/licenses/by-nc-nd/4.0/>).

Introduction

Hypercalcemia, primarily attributed to single parathyroid adenomas, is a well-recognized manifestation of primary hyperparathyroidism, accounting for approximately 90% of cases. An overabundance of parathyroid hormone (PTH), disturbs the body's

normal calcium balance. However, aphagia/dysphagia is seldom associated with hypercalcemia. Instead, hypercalcemia frequently causes gastrointestinal symptoms, such as anorexia, constipation, and pancreatitis. Nevertheless, primary hyperparathyroidism is usually asymptomatic.¹⁻⁴ Here, we report a patient with aphagia and weight loss over 2 months.

Case Report

A 62-year-old man was admitted to our hospital with a 2-month history of weakness, periodic vomiting, and involuntary

Abbreviation: PTH, parathyroid hormone.

* Address correspondence to Dr Duje Čulina, Department of Otorhinolaryngology and Head and Neck Surgery, University Clinical Centre Sestre Milosrdnice, Vinogradska cesta 26, Zagreb 10000, Croatia.

E-mail address: dujeculina5@gmail.com (D. Čulina).

<https://doi.org/10.1016/j.aace.2024.02.004>

2376-0605/© 2024 AAACE. Published by Elsevier Inc. This is an open access article under the CC BY-NC-ND license (<http://creativecommons.org/licenses/by-nc-nd/4.0/>).

weight loss of >20 kg due to severe dysphagia progressing to aphagia, complete inability to swallow liquids or solids in the last 2 days before admission. His medical history included hip arthroplasty performed 4 months earlier in another institution, with no mention of hypercalcemia in perioperative laboratory findings. The initial otorhinolaryngologic examination did not show abnormalities, and endoscopic findings showed normal vocal cord motility without salivary retention in the hypopharynx. Esophagogastroduodenoscopy verified a small hiatal hernia without any obstructive mass in the esophagus and during the procedure, and a nasogastric tube was placed because of aphagia. Contrast-enhanced neck computed tomography showed massive ventral spondylophytes of the cervical spine at the level of the postcricoid segment of the hypopharynx, pushing the prevertebral structures ventrally, which were considered as the primary cause of dysphagia. An additional finding was a mass measuring $3.6 \times 2.6 \times 2.5$ cm behind the left thyroid lobe, shown to be hypoechoic by neck ultrasonography (Fig. 1). The PTH, serum calcium, and ionized calcium levels were 102 pmol/L (reference range, 1.8-7.9 pmol/L), 4.12 mmol/L (2.14-2.53 mmol/L), and 2.13 mmol/L (1.18-1.32 mmol/L), respectively, and the serum albumin level was within the normal range. An intense technetium-99m sestamibi uptake score was observed on scintigraphy at the same localization, which was consistent with a hyperfunctional parathyroid gland. Ultrasound-guided fine aspiration cytology examination verified a parathyroid adenoma. Transcervical minimally invasive left inferior parathyroidectomy was performed without exposition of the 3 normal parathyroid glands, leading to a decrease in the PTH level from 74.60 pmol/L at the start of surgery to 12.80 pmol/L within 15 minutes after parathyroid gland removal. Pathohistologic findings verified a parathyroid gland adenoma. The postoperative course was uncomplicated, showing stable PTH and serum calcium levels of 4.54 pmol/L and 2.25 mmol/L, respectively, and no systemic or wound-related complications. The patient's dysphagia resolved within the first 3 postoperative days, and the nasogastric tube was removed. Follow-up magnetic resonance imaging confirmed ventral displacement of the hypopharynx with cervical spondylophytes; however, further surgical treatment was halted because of complete disappearance of the patient's symptoms during the 1-year follow-up period (Fig. 2). The long-term follow-up showed normal calcium serum levels without any signs of hungry bone syndrome.

Discussion

Severe dysphagia is a rare initial presentation of hypercalcemia.⁵ The differential diagnosis of severe dysphagia should rule out a physical structure displacing the esophagus, such as a tumor mass, diverticulum, or vertebral spondylophytes. However, a systemic metabolic disorder, such as hypercalcemia due to a primary parathyroid adenoma, may also impair esophageal mobility as a silent underlying cause. Because the nasogastric tube was removed on the first postoperative day due to complete resolution of symptoms, a plausible connection between hypercalcemia and dysphagia in our case may be assumed.

The pathophysiologic mechanism of hypercalcemia-induced severe dysphagia may be explained by the calcium ion imbalance impacting esophageal neuromuscular transmission and

Highlights

- Primary hyperparathyroidism, often caused by a parathyroid adenoma, is the most common cause of hypercalcemia
- Dysphagia/aphagia can be caused by hypercalcemia
- Surgical removal of adenoma result in normalization of the serum calcium levels
- Severe dysphagia is not a typical presenting symptom of parathyroid adenoma; however, it should be noted in the differential diagnosis

Clinical Relevance

The learning point of this case report would be to establish a connection between metabolic disorders and aphagia. Although severe dysphagia is not a typical presenting symptom of parathyroid adenoma, it should be noted in the differential diagnosis.

muscular contraction. Rapid influx of calcium ions into the neuromuscular synapse leads to excessive release of acetylcholine, paralyzing the musculature. On the other hand, a case may be made for the increase in the intracellular calcium levels stimulating muscular contractions due to consequent interactions between actin and myosin up to a certain level of serum calcium. When the serum calcium level increases significantly in the long term, it causes depression in the nervous and gastrointestinal systems, manifesting with reduced contractility of smooth muscles due to their higher content of calcium-dependent channels than in the skeletal muscles. The esophagus is histologically divided into the following 2 areas: (1) the upper third consists of the skeletal muscles, and (2) the lower part consists of the smooth muscles. Therefore, the main pathophysiologic explanation of dysphagia ranging to aphagia may be reduced smooth muscle contractions in the lower two thirds of the esophagus.⁶⁻⁹

It is unknown why dysphagia is not present in all patients with severe hypercalcemia, especially in light of such a symptom being rarely reported in hypercalcemia caused by other benign conditions.

When considering other forms of parathyroid pathology, such as parathyroid cysts or spontaneous parathyroid hematomas due to internal bleeding, both may present with varying severity of dysphagia but not hypercalcemia.⁹

This case shows that dysphagia may be considered as an additional adverse effect of primary parathyroid adenoma, especially prior to performing invasive diagnostic procedures, such as repeated endoscopy or esophageal manometry.¹⁰

Conclusion

In this case, severe dysphagia was evidently caused by hypercalcemia. A parathyroid adenoma was responsible for such an unusual symptom complex, whereas surgical removal of adenoma resulted in normalization of the serum calcium levels and disappearance of dysphagia within 24 hours. The learning point of this case report would be to establish a connection between metabolic disorders and dysphagia relevant in the differential diagnosis of patients presenting with dysphagia and electrolyte imbalance.

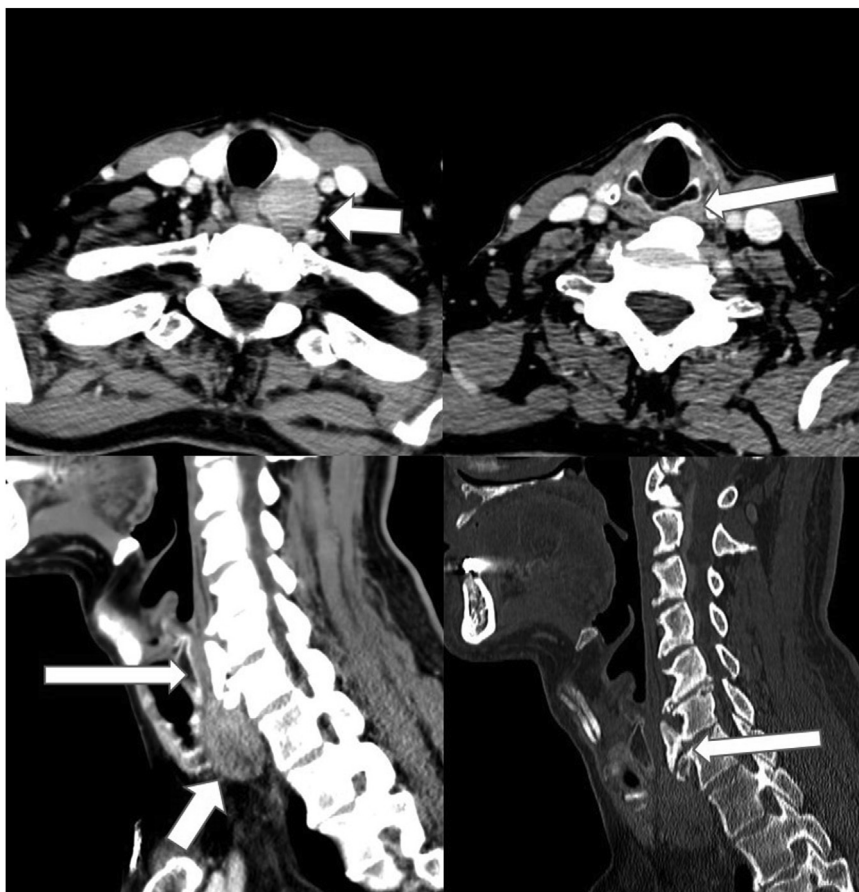

Fig. 1. Computed tomography revealed an oval, well-circumscribed solid mass located posterior to the left lobe of the thyroid gland (short white arrows). The mass showed less enhancement compared with the thyroid gland. Massive anterior osteophytes of the cervical spine at the C6 to C7 vertebral levels were noted, impinging on the posterior wall of the hypopharynx (long white arrows).

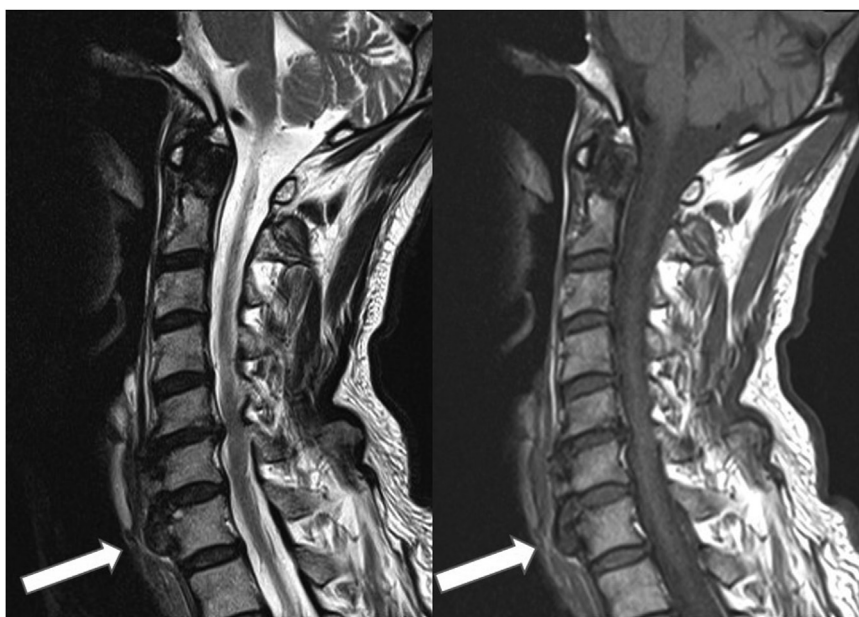

Fig. 2. Sagittal T1- and T2-weighted magnetic resonance imaging revealed disc degeneration at C5 to C6 and C6 to C7 with cervical spondylosis and ventral osteophyte formation. Massive cervical osteophytes at C6 to C7 caused indentation of the posterior pharyngeal wall.

Disclosure

The authors have no conflicts of interest to disclose.

References

1. Gujral JS, El-Choufi L. Spontaneous haemorrhagic infarction of parathyroid adenoma. *J Indian Acad Clin Med.* 2007;8:352–354.
2. AACE/AAES Task Force on Primary Hyperparathyroidism. The American Association of Clinical Endocrinologists and the American Association of Endocrine Surgeons position statement on the diagnosis and management of primary hyperparathyroidism. *Endocr Pract.* 2005;11(1):49–54. <https://doi.org/10.4158/EP.11.1.49>
3. Villavicencio Kim J, Saraceni C, Vaziri H. Dysphagia in a cancer patient. *Dysphagia.* 2022;37(1):1–3. <https://doi.org/10.1007/s00455-020-10227-7>
4. Bilezikian JP, Khan AA, Silverberg SJ, et al. International Workshop on Primary Hyperparathyroidism. Evaluation and management of primary hyperparathyroidism: summary statement and guidelines from the fifth international workshop. *J Bone Miner Res.* 2022;37(11):2293–2314. <https://doi.org/10.1002/jbmr.4677>
5. Triggs J, Pandolfino J. Recent advances in dysphagia management. *F1000Res.* 2019;8:F1000 Faculty Rev-. <https://doi.org/10.12688/f1000research.18900.1>
6. McCarty EB, Chao TN. Dysphagia and swallowing disorders. *Med Clin North Am.* 2021;105(5):939–954. <https://doi.org/10.1016/j.mcna.2021.05.013>
7. Turner JJO. Hypercalcaemia - presentation and management. *Clin Med (Lond).* 2017;17(3):270–273. <https://doi.org/10.7861/clinmedicine.17-3-270>
8. Skarbinski KF, Glennon E. Dysphagia: a review. *Nurse Pract.* 2020;45(7):9–16. <https://doi.org/10.1097/01.NPR.0000669120.41930.5e>
9. Ahsayen FZ, Haddadi Z, Aggari HE, et al. Dysphagia revealing a giant cystic parathyroid adenoma. *Radiol Case Rep.* 2022;17(10):3556–3558. <https://doi.org/10.1016/j.radcr.2022.06.044>
10. Balcombe NR. Dysphagia and hypercalcaemia. *Postgrad Med J.* 1999;75(884):373–374. <https://doi.org/10.1136/pgmj.75.884.373>